





Acute SARS-CoV-2 alpha variant infection leading to placental insufficiency and fetal distress

Sander Dumont^{1,2}  | Jonas Balduyck^{1,2}  | Marijke Reynders³  |
Lieve Vanwalleghem⁴ | Barbara Lebbe¹ 

¹Department of Gynecology, Obstetrics, and Fertility, AZ Sint-Jan Brugge-Oostende AV, Brugge, Belgium

²Department of Gynecology and Obstetrics, University Hospitals Leuven, Leuven, Belgium

³Department of Microbiology, AZ Sint-Jan Brugge-Oostende AV, Brugge, Belgium

⁴Department of Pathology, AZ Sint-Jan Brugge-Oostende AV, Brugge, Belgium

Correspondence

Barbara Lebbe, Department of Gynecology, Obstetrics, and Fertility, AZ Sint-Jan Brugge-Oostende AV, Ruddershove 10, 8000 Brugge, Belgium.
Email: barbara.lebbe@azsintjan.be

Abstract

The effect of the severe acute respiratory syndrome coronavirus 2 (SARS-CoV-2) Alpha variant (also known as B.1.1.7 lineage, 20I/501Y.V1, the UK variant or VOC 202012/01) infection on pregnancy is currently unknown.

We present a case of a 37-year-old woman admitted to our tertiary hospital at a gestational age of 29 weeks and 1 day because of oligohydramnios with reduced fetal movements for 10 days. About 20 days before admission, she tested positive for SARS-CoV-2 Alpha variant. The following day, due to abnormal cardiotocography, increased brain sparing, and absent end-diastolic flow in the umbilical artery, an urgent cesarean section was performed. The neonate had an uneventful admission to the neonatal intensive care unit. All neonatal samples proved negative for SARS-CoV-2.

Pathological examination of the placenta revealed intervillous fibrin deposition, ischemic necrosis of villi and histiocytic intervillitis, corresponding with the SARS-CoV-2 placentitis triad. The placental tissue demonstrated a high viral load, possibly explaining the acute onset of placental insufficiency and subsequent fetal distress. This case demonstrates the importance of seeking medical care when experiencing reduced fetal movement in SARS-CoV-2 infected patients since acute infection can induce significant placental and subsequent fetal pathology.

KEYWORDS

maternal health, obstetric infection, obstetrics, placenta

1 | INTRODUCTION

COVID-19, the disease caused by severe acute respiratory syndrome coronavirus 2 (SARS-CoV-2) was declared a pandemic by the World Health Organization in March 2020.¹ Several variants of SARS-CoV-2 have since been described. One of the major variants in Western Europe during the time of writing is the SARS-CoV-2 Alpha variant (also known as B.1.1.7 lineage, 20I/501Y.V1, the UK variant, or VOC 202012/01). This variant is more infectious and leads to higher mortality.² The effect of the SARS-CoV-2 Alpha variant on pregnancy is currently unknown.

Due to the novelty of COVID-19, literature concerning the effect of SARS-CoV-2 on pregnancy and fetal outcome is limited and mainly consists of small retrospective cohorts.^{3–5} In women with pre-existing risk factors (hypertension, diabetes, age >35 years, obesity,...), a SARS-CoV-2 infection during pregnancy leads to increased maternal morbidity.⁶ Current literature indicates that true vertical transmission of SARS-CoV-2 is rare at about 3.2%.^{4,7–9} However, pathological lesions caused by SARS-CoV-2 in the placenta have been described.¹⁰

In this case, we present an acute SARS-CoV-2 Alpha variant infection leading to rapid onset placental insufficiency with fetal distress during the second trimester.

2 | CASE PRESENTATION

A 37-year-old patient was referred to our tertiary teaching hospital at a gestational age of 29 weeks and 1 day because of oligohydramnios. The patient was admitted the previous day to a local hospital because of reduced fetal movements. On ultrasound, oligohydramnios was observed with nearly absent fetal movements. A point-of-care test was conducted and could not demonstrate premature rupture of membranes. Because of this obstetric complication and the very preterm gestational age, the patient was transferred to our regional perinatal health care center.

Six years prior, the patient had an uncomplicated pregnancy with a vaginal delivery at term of an infant weighing 3945 g. Otherwise, no relevant history could be noted. Besides a pregnancy supplement, the patient did not use any prescription drugs. Furthermore, she denied cigarette smoking nor the usage of illicit drugs. No SARS-CoV-2 vaccination was administered.

The patient reported reduced fetal movements during the previous 10 days without any additional symptoms. About 20 days before the admission, the patient was infected with the SARS-CoV-2 virus by her husband and had a paucisymptomatic infection with non-severe upper respiratory tract infection symptoms without a fever. The nasopharyngeal polymerase chain reaction (PCR) swab at the time of infection proved positive for SARS-CoV-2 Alpha variant.

At admission, the patient denied any COVID-19 symptoms, only reduced fetal movements were noted. Cardiotocography (CTG) demonstrated a normal fetal pattern according to the International Federation of Gynecology and Obstetrics (FIGO) classification. Blood pressure and urine analysis were normal. Transabdominal ultrasound showed a female singleton in cephalic presentation with an estimated fetal weight of 1320 g, percentile 48. Fetal movements were reduced, however, after stimulation, the fetus responded well. Amniotic fluid was severely reduced with an amniotic fluid index of 4 cm with the deepest pocket of 1.5 cm. Doppler examination of the umbilical artery demonstrated almost absent end-diastolic flow. Doppler assessment of the middle cerebral artery (MCA) indicated brain sparing (pulsatility index 1.19, Z-score -3.21) with normal peak systolic velocities. The a-wave of the ductus venosus was positive. The placenta showed marked calcifications on ultrasound with comma-like densities and indentations, corresponding to Grannum grade 2–3 in focal zones. Nasopharyngeal PCR was still weakly positive for SARS-CoV-2 at admission, as well as serum (low viremia) and urine samples. Blood analysis did not show any abnormal values, indirect Coombs test was negative. Serological screening for classical congenital infections was negative: *Treponema pallidum*, Toxoplasmosis, CMV, Hepatitis B, Hepatitis C, HIV, Rubella, and Parvovirus B12 testing all showed no recent infection. The N-antigen of SARS-CoV-2 immunoglobulin G (IgG) was positive (6.97 index) on admission, indicating previous infection. These specific antinucleocapsid antibodies develop only after infection (not after vaccination) and appear in general within 2–3 weeks after the onset of infection in immunocompetent persons.^{11,12} The patient was admitted for observation. At the referral hospital, dexamethasone for fetal maturation was already administered.

The following day, at a gestational age of 29 weeks 2 days, the CTG demonstrated a FIGO abnormal fetal pattern with greatly reduced variability. Transabdominal ultrasound examination showed absent fetal movements, increased brain sparing (pulsatility index MCA 0.83, Z-score -5.69) and absent end-diastolic flow in the umbilical artery. The a-wave of the ductus venosus was still positive. Due to acute fetal distress, an urgent cesarean section was performed after administration of intravenous magnesium sulfate for fetal neuroprotection. A neonate weighing 1100 g was born with Apgar scores of 4, 4, and 8 after 1, 5, and 10 min, respectively. Umbilical cord blood gas analysis revealed normal values: arterial pH 7.29 with lactate of 4.4 mmol/L; venous pH 7.31 with lactate of 3.9 mmol/L. The neonate was admitted to the neonatal intensive care unit due to its premature age. Further neonatal admission was uneventful with little respiratory distress. Nasopharyngeal PCR was obtained from the neonate on two occasions, each time negative for SARS-CoV-2. Umbilical cord and fetal blood analysis also showed the absence of SARS-CoV-2 RNA. Immunoglobulins were assessed on the umbilical cord blood; these samples demonstrated positive anti-N (nucleocapsid) and anti-S (spike) IgG for SARS-CoV-2, as proof of placental transmission of the maternal antibodies without transfer of the virus itself to the fetus.

Macroscopic examination of the placenta showed multiple white and yellow zones. Microscopic examination of the placenta revealed intervillous fibrin deposition with ischemic necrosis of villi and histiocytic intervillitis (see Figure 1). In the intervillous spaces, multiple histiocytes aggregates were observed with the presence of abundant CD8+ T-cells. PCR analysis of the placenta demonstrated SARS-CoV-2 (high viral load, cycle threshold [Ct] value of 14.8) permeation. Analysis of breast milk showed the presence of anti-N and anti-S IgG for SARS-CoV-2. SARS-CoV-2 whole genome sequencing was performed on the illumina MiSeq using the QiaSeq Direct SARS-CoV-2 assay (Qiagen), identifying the strain as hCoV-19/Belgium/SJ4267039/2021, a mutated strain of SARS-CoV-2 Alpha variant.

All events are plotted on a timeline provided in Figure 2. When available, a Ct value is mentioned. Ct is the cycle threshold of the PCR test, a lower value indicates a higher viral load.¹³ However, the first PCR test of the patient reported a low Ct, indicating a very early infection.

In all clinical samples from mother and neonate, SARS-CoV-2 RNA detection was in first-line performed with a commercial real-time reverse transcriptase-polymerase chain reaction (RT-PCR), the “Cobas® SARS-CoV-2” assay, on the fully automated cobas® 6800 System (Roche) targeting the ORF1 a/b nonstructural region, unique for SARS-CoV-2, besides a conserved region in the structural protein envelope E-gene, selected for pan-Sarbecovirus detection. SARS-CoV-2 RNA presence in cord and fetal blood, and in the placental homogenate was confirmed by a second technique, a laboratory-developed semi-quantitative real-time RT-PCR targeting the N (nucleocapsid) and RdRp (RNase-dependent RNA polymerase) genes, after an extraction of the viral RNA present in the clinical samples on the QiaSymphony (Qiagen). IgG antibodies, including neutralizing antibodies, to the receptor binding domain of the S1 subunit of the spike (S) protein of SARS-CoV-2 were determined in serum by a chemiluminescent microparticle immunoassay

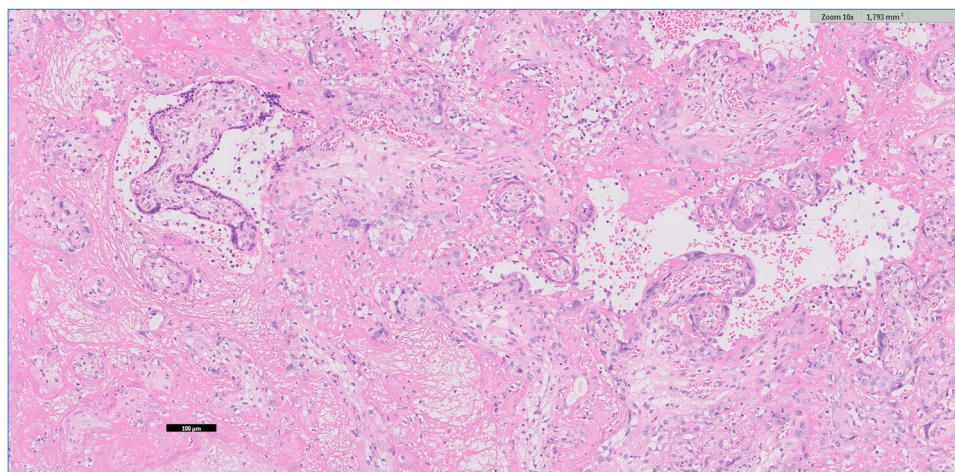


FIGURE 1 Placenta (hematoxylin and eosin staining, ocular $\times 10$ and objective $\times 10$) demonstrating the SARS-CoV-2 placentalitis triad: perivillous fibrin deposition with ischemic changes and necrosis of the villi. The intervillous space shows inflammatory cells and histiocytes. SARS-CoV-2, severe acute respiratory syndrome coronavirus 2

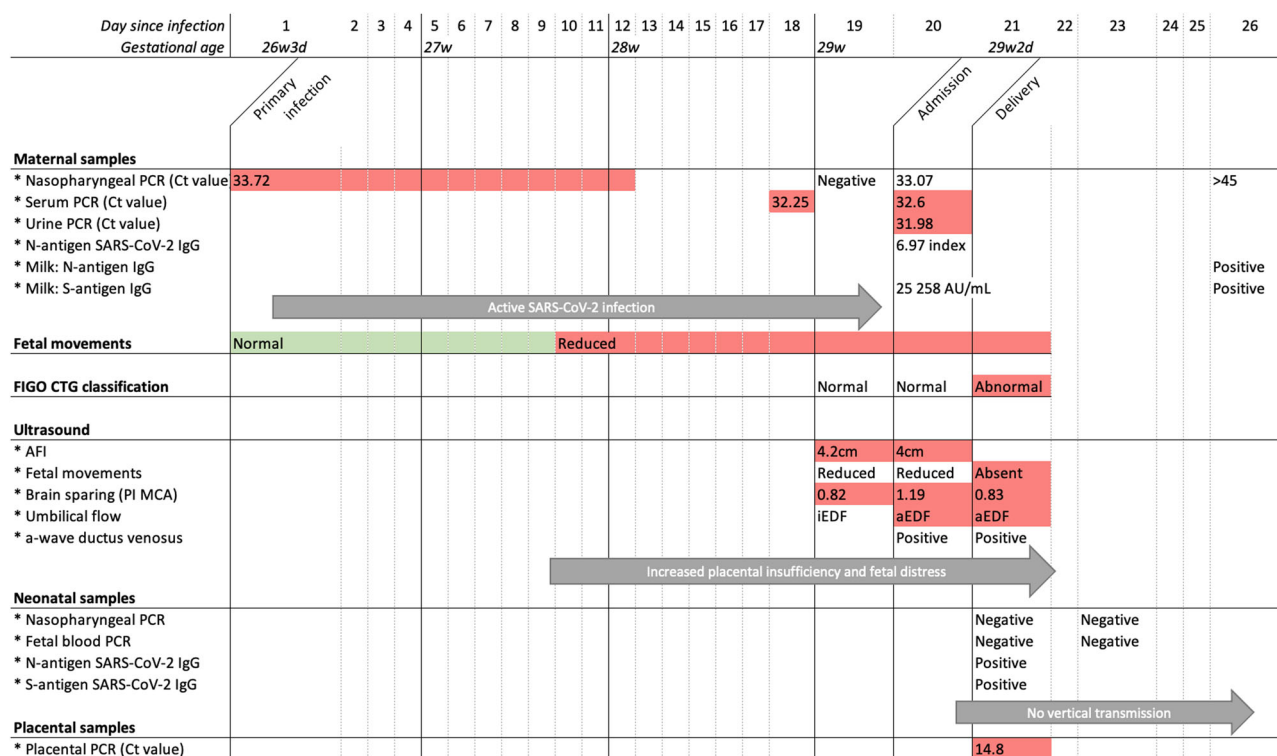


FIGURE 2 Timeline displaying clinical and biochemical course of the case Color code: red = abnormal findings; green = normal findings. aEDF, absent end-diastolic flow; AFI, amniotic fluid index; CTG, cardiotocography; Ct value, cycle threshold; FIGO, International Federation of Gynecology and Obstetrics; iEDF, intermittent end-diastolic flow; MCA, middle cerebral artery; PCR, polymerase chain reaction; PI, pulsatility index

(CMIA) on the ARCHITECT i System according to the manufacturer's instructions (SARS-CoV-2 IgG II Quant assay; Abbott). The qualitative detection of serum IgG antibodies to the nucleocapsid (N) protein of SARS-CoV-2 was performed using a CMIA on the same ARCHITECT i analyser (SARS-CoV-2 IgG assay; Abbott). A signal/cut-off (S/CO) ratio of ≥ 1.4 was interpreted as reactive.

3 | DISCUSSION

This case report demonstrated a possible effect of SARS-CoV-2 Alpha variant on the placental tissue leading to abnormal fetal perfusion. To our knowledge, this is the first case to describe such an extent of fetal distress.

Although COVID-19 does not appear to increase stillbirth or early neonatal death, preterm birth has been associated with SARS-CoV-2 infection, either spontaneous or iatrogenic.^{14–16} In this case, absent fetal movements, increased brain sparing, and absent end-diastolic umbilical blood flow indicates impending fetal death.¹⁷ Additionally, rapid onset abnormal CTG monitoring indicate acute fetal distress. As such, we expect if no interventions were undertaken, stillbirth could occur in this case.

The newborn did test negative for SARS-CoV-2 on multiple occasions, correlating with findings true vertical transmission of SARS-CoV-2 is rare.^{4,7,8} As such we contemplate that the fetal distress is caused due to infection-related placental changes rather than the direct influence of SARS-CoV-2 on the fetus. The additional ischemic necrosis of villi and necrotizing chorioamnionitis indicate an infectious process.

The effect of SARS-CoV-2 on placental tissue is already described by multiple papers, main histopathological findings are fetal and maternal vascular malperfusion and/or placental inflammation.^{3,10,18,19} Although the literature is varied between the full extent of the histopathological findings caused by SARS-CoV-2, the main trend is to diagnose significant vascular changes. Chorioamnionitis on the other hand is a less clear characteristic of SARS-CoV-2, potentially indicating a secondary infection rather than a primary response to this viral infection.^{10,20} Although these placental changes are significantly more present in SARS-CoV-2 infected patients, the pathophysiology potential clinical outcomes are yet to be clearly determined. A recent paper by Watkins et al.²¹ defined SARS-CoV-2 placentitis by the triad of histiocytic intervillitis, perivillous fibrin deposition, and trophoblast necrosis. SARS-CoV-2 placentitis has the potential to cause fetal demise and transplacental infection, the former has been demonstrated by this case since fetal demise was expected without expedited delivery.²¹ Chronic histiocytic intervillitis together with syncytiotrophoblast necrosis is a rare pathological finding, but has been associated with transplacental transmission of SARS-CoV-2.²² In our case, the SARS-CoV-2 placentitis triad has also been observed, agreeing with earlier findings reporting a rapid and intra-placental inflammatory response. Histiocytic intervillitis with syncytiotrophoblast necrosis has been perceived in this case, although with more evidence for an acute and active intervillitis rather than a chronic one. While this is considered a risk factor for transplacental transmission, this did not occur in the presented case.

PCR analysis of the placental tissue showed a high viral load (Ct value 14.8). When reviewing the literature, no mentioning of Ct values in placental tissue could be retrieved. We contemplate that this high viral load could be a mediator of this placental insufficiency. In comparison, in adult patients, lower Ct values (correlating with higher viral load) could be linked to worse outcomes, although this is a topic of controversy.¹³

Fetal Doppler assessment in COVID-19 patients is reported to be similar to those in healthy patients, although disagreement exists.^{23–25} Furthermore, in COVID-19 pregnant patients, impaired placental function or Doppler abnormalities seem not to be linked

with fetal growth restrictions in second half of pregnancy.⁹ In our case, abnormal Doppler signals were present from the both umbilical artery as well as the MCA, indicating fetal distress.¹⁷ We propose these alterations in fetal hemodynamics are attributed to a sub-optimal placental blood flow since previous studies indicate normal Doppler indices in COVID-19 disease. Furthermore, oligohydramnios is a sign of severe placental insufficiency.¹⁷

The SARS-CoV-2 Alpha variant is reported to significantly increase adult mortality, up to a hazard of death of 61% higher in comparison with other variants.² Additionally, a more severe COVID-19 illness in adults is reported with this variant.² When reviewing the literature, no information could be retrieved concerning possible increased risk in pregnancy due to this variant. This warrants further reporting of obstetric complications due to infection with the Alpha variant, as well as other variants.

This case report indicates that an acute SARS-CoV-2 infection could lead to severe and rapid onset placental insufficiency with fetal distress. The obstetric implications of an infection with SARS-CoV-2 Alpha variant infection are unknown and further reporting of complications and associated pathological findings is imperative. Even during the acute highly infectious phase of SARS-CoV-2, patients must not refrain from searching urgent medical care when experiencing reduced or absent fetal movements since acute infection can induce significant placental and subsequent fetal pathology. Patients should be given clear instructions on how to proceed in case of reduced or absent fetal movements.

ACKNOWLEDGEMENTS

The authors would like to thank Melek Ahmed, M.D. for aiding in the pathological analysis.

FUNDING

The funding information is not available.

CONFLICT OF INTERESTS

The authors declare that there are no conflict of interests.

AUTHOR CONTRIBUTIONS

Sander Dumont and **Jonas Balduyck**: drafted initial manuscript. Literature search was conducted by all authors. **Marijke Reynders**: conducted further research on the analyzed samples and provided technical guidance. **Lieve Vanwalleghem**: provided microscopic images and reviewed pathology sections. All authors read, reviewed, and approved the final manuscript.

ETHICS STATEMENT AND CONSENT TO PARTICIPATE

Case reports are waived from institutional board review at our institution. Written and signed informed consent of the patient was obtained concerning this case report before submitting this article. This form can be made available on request.

DATA AVAILABILITY STATEMENT

The data that support the findings of this study are available from the corresponding author upon reasonable request.

ORCID

Sander Dumont  <https://orcid.org/0000-0001-5660-1591>

Jonas Balduyck  <https://orcid.org/0000-0003-3002-8058>

Marijke Reynders  <https://orcid.org/0000-0003-2079-1279>

Barbara Lebbe  <https://orcid.org/0000-0002-8671-878X>

REFERENCES

- World Health Organization. WHO Director-General's opening remarks at the media briefing on COVID-19 – 11 March 2020. Published 2020. Accessed June 16, 2021. <https://www.who.int/director-general/speeches/detail/who-director-general-s-opening-remarks-at-the-media-briefing-on-covid-19-11-march-2020>
- Davies NG, Jarvis CI, CMMID COVID- Working G, et al. Increased mortality in community-tested cases of SARS-CoV-2 lineage B.1.1.7. *Nature*. 2021;3(January):270-274. doi:10.1038/s41586-021-03426-1
- Patberg ET, Adams T, Rekawek P, et al. Coronavirus disease 2019 infection and placental histopathology in women delivering at term. *Am J Obstet Gynecol*. 2021;224(4):382.e1-382.e18. doi:10.1016/j.ajog.2020.10.020
- Di Mascio D, Sen C, Saccone G, et al. Risk factors associated with adverse fetal outcomes in pregnancies affected by Coronavirus disease 2019 (COVID-19): a secondary analysis of the WAPM study on COVID-19. *J Perinat Med*. 2020;48(9):950-958. doi:10.1515/jpm-2020-0355
- Poon LC, Yang H, Dumont S, et al. ISUOG Interim Guidance on coronavirus disease 2019 (COVID-19) during pregnancy and puerperium: information for healthcare professionals—an update. *Ultrasound Obstet Gynecol*. 2020;55(6):848-862. doi:10.1002/uog.22061
- Sentilhes L, De Marcillac F, Jouffrieau C, et al. Coronavirus disease 2019 in pregnancy was associated with maternal morbidity and preterm birth. *Am J Obstet Gynecol*. 2020;223(6):914.e1-914.e15. doi:10.1016/j.ajog.2020.06.022
- Mahyuddin AP, Kanneganti A, Wong JLL, et al. Mechanisms and evidence of vertical transmission of infections in pregnancy including SARS-CoV-2. *Prenat Diagn*. 2020;40(13):1655-1670. doi:10.1002/pd.5765
- Martinez-Portilla RJ. Vertical transmission of coronavirus disease 2019. *Am J Obstet Gynecol*. 2021;224(3):328-329. doi:10.1016/j.ajog.2020.11.013
- Di Mascio D, Buca D, Berghella V, et al. Counseling in maternal-fetal medicine: SARS-CoV-2 infection in pregnancy. *Ultrasound Obstet Gynecol*. 2021;57(5):687-697. doi:10.1002/uog.23628
- Sharps MC, Hayes DJL, Lee S, et al. A structured review of placental morphology and histopathological lesions associated with SARS-CoV-2 infection. *Placenta*. 2020;101(August):13-29. doi:10.1016/j.placenta.2020.08.018
- Van Elslande J, Oyaert M, Ailliet S, et al. Longitudinal follow-up of IgG anti-nucleocapsid antibodies in SARS-CoV-2 infected patients up to eight months after infection. *J Clin Virol*. 2021;136:104765. doi:10.1016/j.jcv.2021.104765
- Ebinger JE, Fert-Bober J, Printsev I, et al. Antibody responses to the BNT162b2 mRNA vaccine in individuals previously infected with SARS-CoV-2. *Nat Med*. 2021;27(6):981-984. doi:10.1038/s41591-021-01325-6
- Rao SN, Manissero D, Steele VR, Pareja J. A narrative systematic review of the clinical utility of cycle threshold values in the context of COVID-19. *Infect Dis Ther*. 2020;9(3):573-586. doi:10.1007/s40121-020-00324-3
- WAPM (World Association of Perinatal Medicine) Working Group on C. Maternal and perinatal outcomes of pregnant women with SARS-CoV-2 infection. *Ultrasound Obstet Gynecol*. 2021;57(2):232-241. doi:10.1002/uog.23107
- Dubey P, Reddy SY, Manuel S, Dwivedi AK. Maternal and neonatal characteristics and outcomes among COVID-19 infected women: an updated systematic review and meta-analysis. *Eur J Obstet Gynecol Reprod Biol*. 2020;252:490-501. doi:10.1016/j.ejogrb.2020.07.034
- Mullins E, Hudak ML, Banerjee J, et al. Pregnancy and neonatal outcomes of COVID-19: coreporting of common outcomes from PAN-COVID and AAP-SONPM registries. *Ultrasound Obstet Gynecol*. 2021;57(4):573-581. doi:10.1002/uog.23619
- Baschat AA. Planning management and delivery of the growth-restricted fetus. *Best Pract Res Clin Obstet Gynaecol*. 2018;49:53-65. doi:10.1016/j.bpobgyn.2018.02.009
- Baergen RN, Heller DS. Placental pathology in covid-19 positive mothers: preliminary findings. *Pediatr Dev Pathol*. 2020;23(3):177-180. doi:10.1177/1093526620925569
- Blasco Santana L, Miraval Wong E, Álvarez-Troncoso J, Sánchez García L, Bartha JL, Regojo-Zapata RM. Maternal and perinatal outcomes and placental pathologic examination of 29 SARS-CoV-2 infected patients in the third trimester of gestation. *J Obstet Gynaecol Res*. 2021;47(6):2131-2139. doi:10.1111/jog.14784
- Menter T, Mertz KD, Jiang S, et al. Placental pathology findings during and after SARS-CoV-2 infection: features of villitis and malperfusion. *Pathobiology*. 2021;88(1):69-77. doi:10.1159/000511324
- Watkins JC, Torous VF, Roberts DJ. Defining severe acute respiratory syndrome coronavirus 2 (SARS-CoV-2) placentalitis: a report of 7 cases with confirmatory in situ hybridization, distinct histomorphologic features, and evidence of complement deposition. *Arch Pathol Lab Med*. 2021. doi:10.5858/arpa.2021-0246-SA
- Schwartz DA, Baldewijns M, Benachi A, et al. Chronic histiocytic intervillitis with trophoblast necrosis is a risk factor associated with placental infection from coronavirus disease 2019 (COVID-19) and intrauterine maternal-fetal severe acute respiratory syndrome coronavirus 2 (SARS-CoV-2) transm. *Arch Pathol Lab Med*. 2021;145(5):517-528. doi:10.5858/arpa.2020-0771-SA
- Ayhan SG, Tanacan A, Atalay A, et al. Assessment of fetal Doppler parameters in pregnant women with COVID-19 infection: a prospective case-control study. *J Perinat Med*. 2021;49:697-701. doi:10.1515/jpm-2020-0512
- Rizzo G, Mappa I, Maquina P, et al. Effect of SARS-CoV-2 infection during the second half of pregnancy on fetal growth and hemodynamics: a prospective study. *Acta Obstet Gynecol Scand*. 2021;100(6):1034-1039. doi:10.1111/aogs.14130
- Anuk AT, Tanacan A, Yetiskin FDY, et al. Doppler assessment of the fetus in pregnant women recovered from COVID-19. *J Obstet Gynaecol Res*. 2021. 2021 May;47(5):1757-1762. doi:10.1111/jog.14726

How to cite this article: Dumont S, Balduyck J, Reynders M, Vanwalleghem L, Lebbe B. Acute SARS-CoV-2 Alpha variant infection leading to placental insufficiency and fetal distress. *J Med Virol*. 2022;94:1196-1200. doi:10.1002/jmv.27379